CHAPTER CONTENTS

8

Sporting injuries

A. INJURY TO THE HAND AND WRIST IN SPORT

W Bruce Conolly, Mark Perko and Rosemary Prosser

GENERAL PRINCIPLES

Hand therapists and surgeons are being called upon to treat sport- and exercise-related injuries more and more. About one-third of all such injuries occur in the hand and wrist. Fortunately, the majority are minor, and treatment is straightforward. However, some major injuries are not recognised until it is too late for effective treatment.

Many of these injuries are sports-specific and an understanding of the mechanism of injury, the requirement of the sport and the needs of the athlete or enthusiast is important to the diagnosis and treatment.

History taking with special reference to the mechanism of injury must never be omitted. The anatomical structures in the hand are intricate, complex and confined. This makes careful and precise observation and palpation mandatory for clinical diagnosis.

Failure to X-ray and failure to re-X-ray (e.g. fractured scaphoid) will often lead to misdiagnosis.

Hand and wrist injuries are common, because of the involvement of the hand and wrist in a wide range of sporting and functional activities.

Figure 8.1 Modification of equipment: the grip on this man's golf club was made larger with a grip-enhancing material to increase grip adhesion. It was also necessary to support the left osteoarthritic wrist with a wrist support to maintain the wrist in maximal extension.

CLASSIFICATIONS

Sporting injuries may be classified as relatively minor – e.g. abrasions, contusions and sprains, fracture of the neck of the fifth metacarpal – or major e.g. fractures involving the proximal interphalangeal (PIP) joint, scaphoid fracture, scapholunate ligament rupture.

Hand injuries may also be classified according to the tissue of injury: ligaments, joints, bones, tendon, neurovascular structures, skin and soft tissue.

Injuries may also be classified as open or closed from direct or indirect force – traction, compression, avulsion, twisting, angulation – or repetitive stress injuries.

Rehabilitation usually involves some type of support splinting and an exercise programme. Modification of the sporting equipment (Fig. 8.1) and/or technique may also be necessary in order for the athlete to return to the sport: this should be done in conjunction with the coach. Splinting or taping (Fig. 8.2) may also be necessary to enable an early return to sport following the injury.

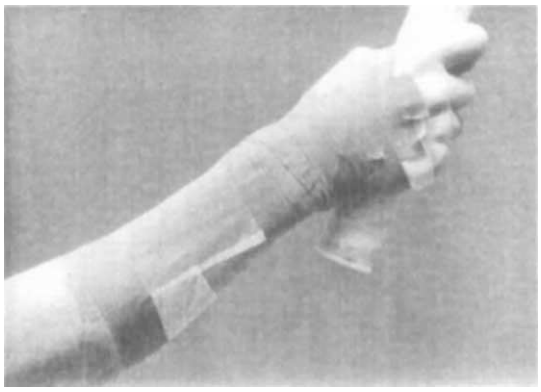

Figure 8.2 Taping is often preferred by the athlete in competition: it is not bulky and provided it is applied correctly can give appropriate support. Tape should be reapplied during competition breaks, as it tends to loosen and stretch out slightly with vigorous motion and perspiration. Taping for a tennis player with ulnar carpal instability is shown here.

Many people become involved following hand injuries in an athlete. The injured person himself is often young and will have two careers – a sporting career and a business or professional career. The involvement of the team coach, therapist, the team doctor and family members will also affect treatment.

LIGAMENT INJURIES IN THE HAND AND WRIST

Ligament injuries[1] are the most common of all sporting injuries in the hand and wrist. They have minimal signs but maximal disability and are often badly treated. The common ligament injuries in the athlete include:

- lateral ligament injury of a digit, e.g. ulnar collateral ligament (UCL) of the metacarpophalangeal (MP) joint of the thumb (skier's thumb)
- hyperextension injury of a digit, e.g. of the PIP joint, leading to rupture of the palmar plate or lateral ligaments

- scapholunate ligament injury at the wrist caused by a fall on the outstretched hand.

Ligament injuries may be classified as:

1. sprain
2. rupture
3. dislocation
4. fracture dislocation.

Sprain injuries to ligaments and joint capsules

Here there is no instability. The management should be supportive strapping and early range of movement within the limit of discomfort. An X-ray should always be taken to exclude a hidden fracture. One must be sure that it is a sprain, i.e. incomplete tearing of fibres, and not a rupture.

Ligament rupture

Ligament rupture occurs in the thumb at the UCL, in the fingers at the palmar plate or lateral ligament of the PIP joint. Complete ligament ruptures are best treated by surgical repair.

Skier's thumb

Anatomy and pathology

When a skier falls, the pole forces the thumb into abduction and extension, stressing the UCL of the MP joint of the thumb. There may be rupture of the UCL at its mid-substance or at either end and there may be a fracture or fracture dislocation of the metacarpophalangeal joint. This injury can also occur in ice hockey and in other games.

Diagnosis

There will be tenderness over the site of ligament rupture, with significant bruising and swelling. The joint will probably be unstable: always compare with the other thumb MP joint. There is often less pain with a complete rupture than with a sprain or an incomplete rupture.

The ligament may be displaced and become lodged between the ruptured end of the ligament and its attachment to the base of the proximal phalanx (Stener lesion).[2]

Management

The first-aid management should include ice packs and strapping for gentle compression and support to avoid further damage.

If one suspects a complete rupture, surgical repair is indicated. Following this, immobilise the repaired ligament for 4–6 weeks in a splint. Begin early interphalangeal joint exercises in the first postoperative week. Gentle thumb MP extension/flexion exercises can be commenced at 4 weeks. Strengthening exercises for the thumb and grip are not commenced until 6 weeks postoperatively. Incomplete ruptures may be treated conservatively with a thumb spica for 5–6 weeks.

Healing and complications

Incomplete diagnosis and incomplete management may lead to permanent instability of this ligament system, with weak grasp and later osteoarthritis.

Specific tip

If IP flexion is not at least half-range by 2 weeks, passive flexion exercises need to be commenced and/or an IP flexion strap worn for 30 min twice a day or more (Fig. 8.3).

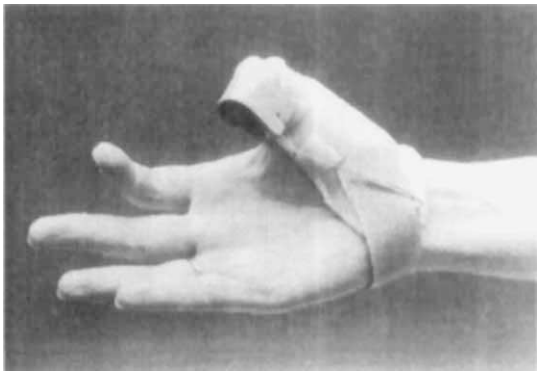

Figure 8.3 A skier's thumb UCL injury requires a splint for protection so that the ligament does not stretch out while it is healing. A flexion strap is worn intermittently for 30 min twice a day or longer if flexion is not 50% of the contralateral side by 2 weeks post-injury.

PIP joint dislocation

Dislocation can occur at any joint level. At the PIP joint level it can be particularly disabling for both grasp and release. Reduction may seem easy but the joint may redislocate just as easily due to instability.

PIP joint dislocations are common in ball sports, particularly football. The force of the football hitting the fingertip hyperextends the PIP joint, causing an avulsion of the distal attachment of the volar plate at the base of the middle phalanx. This may cause an avulsion fracture.

Reduction under a local anaesthetic digital block with traction and a volar directed force over the dorsally displaced middle phalanx will usually suffice.

Therapy for simple dislocations

If a dislocation has been reduced and is stable and there is no associated fracture, simple buddy strapping and early range of motion (ROM) exercises will suffice.

If the joint is only stable in flexion at the PIP joint, an extension block splint in 30 degrees of flexion will be required for 4–6 weeks.

If the injury is more severe and the joint unstable, then direct repair of the fracture or the ligament system may be necessary.

Therapy for severe dislocations

Where the dislocation is associated with a soft tissue and skin wound, often with exposure of the flexor tendons, the wound should be thoroughly cleaned prior to reducing the dislocation to avoid and minimise the chance of infection. Always X-ray after reduction of dislocation to check the accuracy of the reduction and the absence of fracture.

Post-reduction therapy for severe dislocations

Following reduction, the joint should be protected in a dorsal blocking splint in approximately 30 degrees of flexion for 4–6 weeks. Distal interphalangeal (DIP) joint exercises should be commenced within a few days. If the joint is stable, PIP joint exercises in the splint can also be started in the first week. End-range extension should be avoided for approximately 3 weeks. If there is some concern regarding stability and surgical treatment has been ruled out, PIP exercises should not be commenced for 4 weeks.

The patient may develop a flexion contracture due to the soft tissue injury involved in the dislocation. This can be remedied by night-time extension splintage, which is usually commenced 4–6 weeks following reduction. Minor flexion contractures can be treated with a neoprene sleeve, which provides a gentle extension force while still allowing flexion (Fig. 8.4); this type of sleeve may also be appropriate when returning to sport.

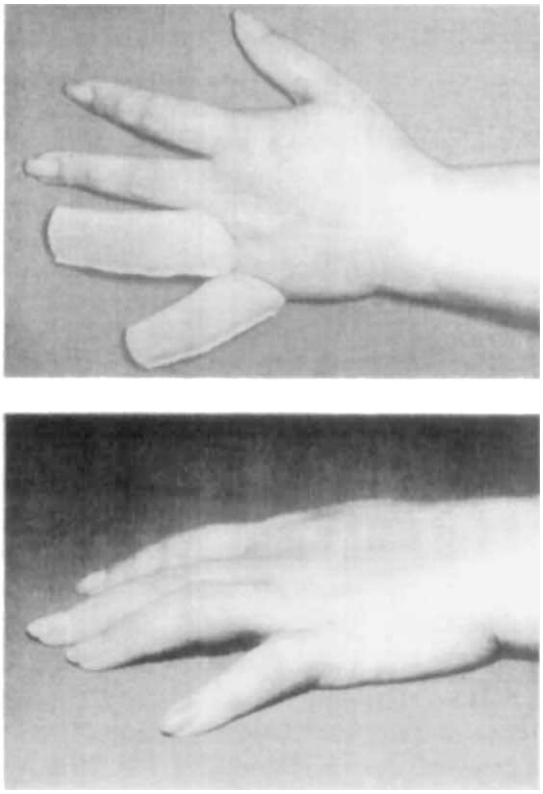

Figure 8.4 A neoprene sleeve (A) provides both support for the joint and a gentle extension force to alleviate minor PIP flexion contractures for the PIP joint following ligamentous injury (B) at this level.

Specific tips

DIP joint exercises are important. DIP flexion glides the flexor tendon, intrinsics, long extensors and oblique retinacular ligament, all of which can become gummed down in the healing tissue at the PIP joint level.

Scapholunate ligament injuries

The scaphoid is the key to normal carpal kinematics and wrist stability. When the ligaments connecting it to the lunate and the volar radius are ruptured by a dorsal extension, ulnar deviation and supination injury, the scaphoid separates from the lunate and rotates vertically, causing carpal collapse. If untreated, this can lead to disabling instability and oesteoarthritis.[3]

The clinical features include diffuse wrist pain and tenderness over the scapholunate ligament dorsally. The wrist is swollen and movement restricted. There may be a wrist haemarthrosis. Displacement of the scaphoid will lead to collapse of the midcarpal joint. The scaphoid shift test (Watson test) will be positive. This is positive if there is dorsal pain over the scapholunate interval and increased mobility of the scaphoid; sometimes there is a click as the scaphoid jumps over the rim of the radius. X-ray may show a gap between the scaphoid and lunate.

Acute scapholunate ligament injuries should be treated primarily by surgical open reduction and ligament repair. Postoperative therapy is described in Chapter 3F.

FRACTURES IN THE HAND AND WRIST

Fractures[4] are common in contact sports. The type of fracture should be diagnosed and checked for displacement, rotation, alignment and joint involvement.

Fractures of the thumb

Intra-articular fractures need to be distinguished from extra-articular fractures as they require more comprehensive treatment, particularly reduction.

Fractures of the base of the metacarpal

Extra-articular fractures of the first metacarpal can be managed by a thumb spica cast for 3 or 4 weeks.

Intra-articular fractures of the thumb include Bennett's fracture. This fracture is often caused by clenched fist injury due to the axial compression load across the first carpometacarpal (CMC) joint. This is really a fracture dislocation which requires reduction of both fracture and the dislocated first metacarpal at the CMC joint.

In the past, K-wire fixation after reduction was advised but open reduction internal fixation (ORIF) with a screw (Fig. 8.5) gives better fixation and is the preferred method (if the avulsed fragment of bone involves more than one-third of the joint surface). An unrecognised and untreated Bennett's fracture dislocation can lead to osteoarthritis of the CMC joint.

Fractures of the metacarpal neck and shaft

A fracture analogous to the Bennett's fracture can occur at the base of the fifth metacarpal and require similar treatment.

Most metacarpal shaft fractures are stable. Rotational alignment should always be checked by assessing digit alignment with the fingers flexed; the malalignment may not be obvious with the finger extended.

Metacarpal neck fractures, e.g. boxer's fracture of the fifth metacarpal neck

Substantial angulation (up to 40–50 degrees) can be accepted because of the great mobility of the CMC and the MP joint of the little finger.

Angulation is not acceptable in neck fractures of the index and middle fingers.

Phalangeal fractures

Phalangeal fractures are more difficult to treat. If they are undisplaced and stable, buddy strapping will suffice. Follow-up check X-ray to detect

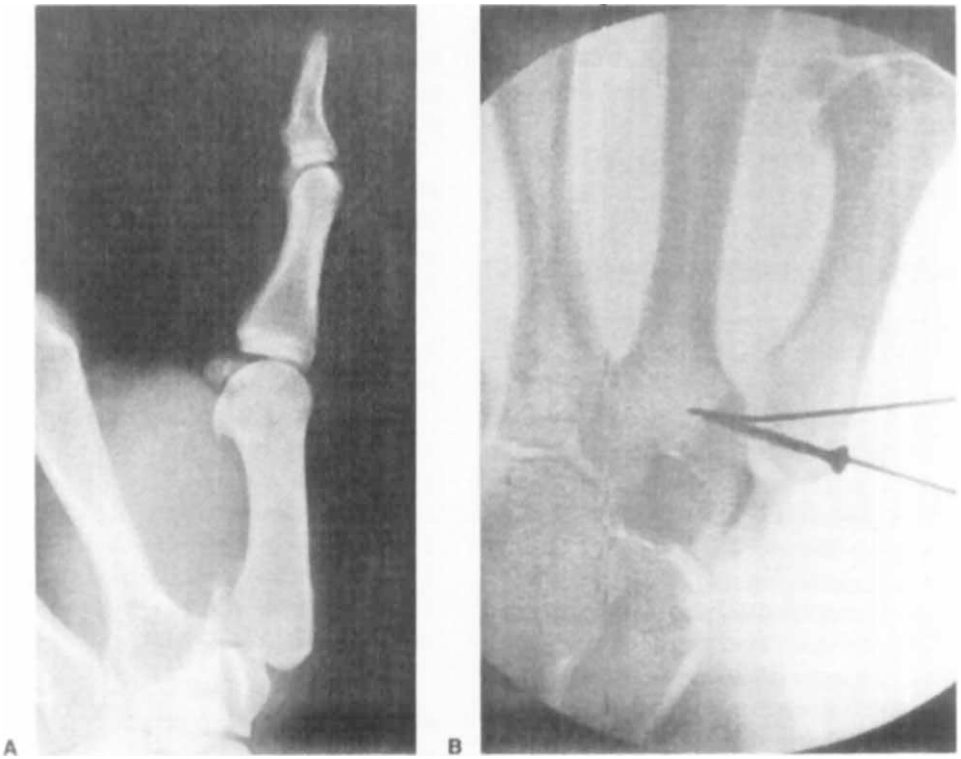

Figure 8.5 Bennett's fracture (A) treated by open reduction and internal fixation (ORIF) with a screw (B).

subsequent displacement of the fracture may be necessary in some cases, e.g. spiral fractures.

A displaced or unstable fracture requires reduction and internal fixation. This allows most athletes to return to their sport earlier than with conservative treatment and with fewer complications.

Therapy for hand fractures

All fractures of the metacarpals and phalanges requiring splinting need to be splinted in the position of safe immobilisation (POSI). The injured digit plus the adjacent one or two digits should be splinted; other digits can be left free. Early return to sport can be facilitated by protection of the fracture with a lightweight thermoplastic splint (1.6 or 2.4 mm). The splint needs to comply with the sports code requirements for the athlete's particular sport. Generally, splints need to be padded externally and taped so that the splint cannot injure other players.

Metacarpal fractures. The IP joints can be left free to move in the case of a metacarpal fracture. The patient should be instructed in ROM exercises for all joints which do not have full range. Emphasis should be placed on MP flexion and EDC (extensor digitorum communis) glide for metacarpal fractures. Gradually, as the patient begins to use the hand, the splint can be exchanged for buddy straps, which should be worn for a further 2–3 weeks.

Phalangeal fractures. Many of these fractures require splintage in the POSI position. ROM exercises should be commenced as soon as the fracture is stable, preferably in the first week. Emphasis should be placed on maintaining full extension while gaining flexion. PIP extension splintage intermittently during the day or at night may be required (see Chapter 2B).

Figure 8.6 X-ray of fracture of the scaphoid (A) requiring open reduction and internal fixation (ORIF) (B).

Fractures of the wrist and carpal instability

Fractures of a scaphoid

These fractures represent the most common and potentially most severe of all carpal bone injuries. Any patient who presents with a painful swollen wrist following a fall on the outstretched hand should be suspected of having a scaphoid fracture or a scapholunate ligament injury.

It is characterised by tenderness and some swelling in the anatomical snuff box. A full series of X-rays with anteroposterior (AP), lateral and oblique views and with radial and ulnar deviation of both wrists are required for comparison.

If there is a suspicion of fracture, a scaphoid cast should be applied for 7–10 days and then the X-ray repeated. If there is doubt, a bone scan should be arranged. Scaphoid fractures present a challenge in management and require vigilance. Even seemingly innocuous fractures can become displaced and fail to unite. Follow-up X-rays (at 10 days) during the period of casting are necessary. Fractures that are displaced from the outset and the proximal pole fractures, even if undisplaced, are associated with a high incidence of long-term complications and are usually managed best by internal fixation (Fig. 8.6).

The indications for surgical reduction and internal fixation include fractures displaced greater than 1 mm, malrotated fractures, scaphoid fractures associated with carpal instability such as scapholunate dissociation and trans-scaphoid perilunate dislocations of the carpus, and some oblique and proximal pole fractures. ORIF in most cases leads to an earlier (6–8 weeks) return of function and ability to work. This in itself in some cases may be an indication for ORIF.

Fractures of the hamate

These fractures often occur in golfers in a non-dominant hand after striking the club on hard ground. The clinical features include point

tenderness over the hamate hook. X-ray may not show this fracture except on carpal tunnel views. A computed tomography (CT) scan may be required. Many of these fractures fail to unite. Excision may be the best long-term treatment.

Fractures of the triquetrium

Dorsal avulsion fracture of the triquetrium is the next commonest carpal injury. There is tenderness over the dorsal aspect of the triquetrium. An X-ray will show the ligamentous avulsion fracture.

Treatment is conservative and involves 3 weeks of immobilisation, followed by an exercise programme to regain mobility and strength. Strong forearm rotation or wrist radial deviation should be avoided for at least 6 weeks.

Fractures of the distal radius

Displaced comminuted fractures will require reduction and, in young patients because of the likelihood of residual collapse following initial reduction, supplementary stabilisation with K-wires or an external fixator may be necessary. Postoperative therapy should follow the same lines as described for distal radial fractures (Chapter 3D).

Fractures of the radial styloid

These fractures may be associated with scapholunate ligament injury even though the fracture is not displaced. If there is a scapholunate ligament injury, management will be more complicated.

Simple radial styloid fractures can be managed in a cast. Scapholunate ligament rupture requires surgical repair.

TENDON INJURIES IN THE HAND IN SPORT

There may be ruptures of the extensor tendons (DIP joint – baseball finger, PIP joint – buttonhole deformity, or the interphalangeal joint of the thumb). There may be rupture of the FDP (flexor digitorum profundus) tendon of the finger (rugby finger).

In general, extensor tendon ruptures which are closed injuries can be treated conservatively with splintage (see Chapter 2E). Closed ruptures of the flexor apparatus are best treated surgically as soon as possible; otherwise, the proximal tendon stump will retract and make reattachment too difficult. For postoperative care, see Chapter 2D.

If diagnosis of FDP rupture is delayed and not made until 3–5 days after injury, it may be inadvisable to attempt surgery but to treat the patient conservatively and concentrate on restoring full movement of the MP and PIP joints. Flexor tendon reconstruction at a later date or DIP joint stabilisation may provide a better functional outcome.

Tenosynovitis can occur from repetitive actions, as in the FCR (flexor carpi radialis) or FCU (flexor carpi ulnaris) tendons of the wrist, or in the first extensor compartment with involvement of the APL (abductor pollicis longus) or EPB (extensor pollicis brevis) tendons (de Quervain's condition) or the ECR (extensor carpi radialis) tendons, the ECU (extensor carpi ulnaris) tendons or the 'intersection syndrome' (see Chapters 2D and 2E).

NEUROVASCULAR INJURIES

Neurovascular injuries include 'bowler's thumb' (neuroma in continuity of the ulnar digital nerve of the thumb from the constant pressure of a bowl), racket ball syndrome, ulnar nerve syndromes and compartment syndromes.

Bowler's thumb

Hand therapy

Hand therapy measures include modification of the grip for bowling and perhaps a change in the ball.

Adaptive devices to protect the nerve from pressure may also be successful. These can be fitted either to the ball or the thumb. Neoprene and silicone elastomere or putty are helpful in the fabrication of these custom-made adaptive devices. If the neuroma proves troublesome in other daily activities, techniques such as the use of TENS (transcutaneous electrical nerve stimulation)

and/or desensitisation may be helpful (see Chapter 7E).

Surgery

In resistant cases, an ulnar digital neurolysis can relieve the problem.

Racket ball syndrome – carpal tunnel syndrome

In racket ball and in other sporting activities – such as rowing, wind surfing and cycling – where prolonged gripping is required, there can be an enlargement of the flexor tenosynovium within the carpal tunnel with secondary compression of the median nerve.

Conservative treatments often suffice, but in resistant cases carpal tunnel decompression may be indicated. In athletes, endoscopic release avoids the interthenar scar and enables an earlier return to sport.

Hand therapy

Conservative management includes stretching the long flexors before and after the sporting activity. Ice, elevation and compression should be applied immediately after the sporting activity if swelling is noted. A splint made of soft material such as neoprene with thermoplastic ribs may be useful depending on the activity causing the carpal tunnel compression. Sporting technique may need modification. In the case of long-distance cycling, alterations in the handle bars, e.g. forearm bars, will decrease the pressure on the carpal tunnel.

Ulnar nerve syndromes

The ulnar nerve can also be trapped at the wrist by a ganglion or by ulnar artery occlusion, in which case the treatment should be directed at the cause.

Ulnar artery thrombosis can occur from a repetitive impact, as in cycling, because of the constant vibration of the bicycle handle, and in sports such as volleyball, handball or karate, where repetitive impact occurs.

Ulnar artery thrombosis presents with local tenderness and swelling, at the hypothenar eminence, ischaemia, often with a painful white ring and little finger. Microemboli may be present.

A bruit may or may not be audible. Prompt referral should be arranged for reconstructive vascular surgery.

Compartment syndromes

There may be increased pressure in the fascial compartment of the forearm, wrist or hand. Severe forearm pain coming on after prolonged vigorous activity may be associated with clinical tension in the forearm compartment. This is seen often in rowers, kayakers or motorcycle racers. If the condition does not respond to local therapy and rest, surgical decompression may be required.

Hand therapy

Conservative management involves completely resting the injured muscles if pain is acute in a POSI resting splint for the hand and/or wrist. Splinting should not be prolonged, e.g. 1–14 days. Local electrophysical agents such as ultrasound, interferential, laser and cryotherapy may prove to be helpful. Massage and appropriate stretching is important. Once the episode has settled, the upper limb should be assessed with particular attention to the length, strength and balance of the musculature. Both concentric and eccentric strength should be evaluated. Following this, an appropriate exercise programme involving both stretching and strengthening exercises is constituted. The rowing/kayaking athlete, coach and therapist may need to discuss the particular stroke technique. Size and shape of the oar/paddle handle and blade may also need scrutiny.

SKIN AND SOFT TISSUE INJURIES

These include abrasions, contusions, calluses and blisters.

Blisters

Blisters occur on the foot and hand. They are best prevented by a common-sense approach to factors known to precipitate them, e.g. proper-fitting socks, footwear and gloves.

The aim of treatment of a blister is to promote healing and prevent infection. Treat by cleaning the blister and skin with antiseptic; aspirate tense blisters with a fine-gauge needle and inject a small dose of tincture of benzoin. If the blister is broken, trim the overlying skin and protect the floor of the blister with a tincture of benzoin and apply protective tape.

Calluses

Treat by light abrasion with a pumice stone. If the callus is large, treat by softening in a warm antiseptic bath and then paring with a fine scalpel.

'Boxer's knuckle'

This condition may include a mild bursa or synovitis or partial or complete rupture of the dorsal capsule of the MP joint of a finger.

Conservative measures are required for all but the ruptured hood, which may need surgical repair. Conservative measures include the fabrication of protective devices that can at least be worn in training sessions. Massage and local electrotherapy modalities are worth exploring but are not always useful. A change in training schedule is necessary in order to give the joint time to heal.

PAEDIATRIC INJURIES

Children and adolescents require specific consideration of their injuries because they are skeletally immature and have open growth plates.

About one-third of all skeletal fractures in children involve the growth plate. Growth plate injuries may be complicated by disturbances in growth, leading to deformity. There may be involvement of the joint surface.

In adolescents, epiphyseal plate injuries are more likely; in the younger child and the skeletally mature person, a ligament or tendon injury is more likely.

Where the growth plate injury is in association with an intra-articular fracture, anatomical reduction, either closed or open, is indicated. With any growth plate injury, the patient should be followed up on a regular basis to recognise and monitor any potential growth disturbance.

One of the more common paediatric hand injuries is a fracture separation of the distal phalangeal epiphysis, which may present as a pseudo mallet finger. X-rays are essential. Anatomical reduction is indicated.

REFERENCES

1. Posner MA: Ligament injuries in the wrist and hand. Hand Clin 4 November, 1992.
2. Stener B: Displacement of the ruptured ulnar collateral ligament of the metacarpophalangeal joint of the thumb. J Bone Joint Surg 44B:869, 1962.
3. Herbert T: The fractured scaphoid. St Louis: Quality Medical Publishing, 1990:173–94.
4. Barton NJ: Fractures of the hand. J Bone Joint Surg 664:159–67, 1984.

B. INJURY OF THE ELBOW AND SHOULDER IN SPORT

Mark Perko

For a comprehensive treatment of the elbow and the shoulder, the reader is referred to Chapters 5 and 6, respectively.

Participation in sports can place considerable demands on both the shoulder and the elbow. Injuries can occur from overuse or direct trauma. Overuse injuries can be reduced by appropriate training and conditioning. Acute injuries will always occur, but attention to participant safety, game codes and the playing environment will reduce these risks. The goal of treatment is to restore function as quickly as possible, but